

CASE REPORT



Chiropractic Management of a Professional Hockey Player with Recurrent Shoulder Instability


Chad E. Moreau, DC,^a and Susan R. Moreau, DC^b

ABSTRACT

Objective: To describe the clinical management of recurrent shoulder instability in a professional hockey player by using chiropractic management and rehabilitation exercises.

Clinical Features: A 23-year-old professional hockey player with recurrent left shoulder pain and instability. He had two previous unsuccessful shoulder operations to correct the instability. He reported that the shoulder “slips out” in positions of abduction and external rotation or when the left arm is moved suddenly above shoulder height. The patient was still playing hockey professionally at the time of the initial visit and did not want to have to take time off for another surgery, so he chose to attempt a conservative approach.

Intervention and Outcome: The patient had undergone strength training for rehabilitation after each of the previous two



shoulder operations and had very strong rotator cuff and scapular musculature. Proprioceptive testing revealed a poor response in the left shoulder compared with the right shoulder. Two subjective outcome measures were used to determine the effectiveness of the treatment protocol in reducing the symptoms of recurrent shoulder instability. Much of the treatment focused on proprioceptive training, soft tissue mobilization, and improving joint function.

Conclusion: This case demonstrates the potential benefit of chiropractic management and proprioceptive exercises to decrease the symptoms of recurrent shoulder instability. (*J Manipulative Physiol Ther* 2001;24:425-30)

Key Indexing Terms: Shoulder Instability; Hockey; Sports Injuries; Chiropractic; Proprioception; Training

INTRODUCTION

A full spectrum of the population from children to professional athletes can have recurrent glenohumeral instability.¹ Shoulder instability can be defined as the loss of shoulder comfort and function as a result of undesirable translation of the humeral head on the glenoid.² The consequences of glenohumeral joint instability, including pain and patient apprehension during certain shoulder movements, are particularly serious for people who use their shoulders during employment or sports activities.³ Recurrent posttraumatic anterior instability of the shoulder affects the young patient most commonly, with recurrence rates as high as 90% in patients with first-time dislocations who are younger than 20 years.⁴

Treatment options range from learning to live with the disability to an aggressive exercise routine to surgical inter-

vention.¹ Most patients who have instability of the shoulder can be well managed without surgery. When treatment fails, modern anatomic repairs achieve stability and function in a high proportion of patients. Sometimes the surgery itself may fail because of incorrect diagnosis, improper surgical technique, or inappropriate rehabilitation.⁵

Professional ice hockey is a fast-paced, physical game that puts high demands on shoulder function.⁶ The shoulder is one of the most common areas of injury in elite-level hockey. Most players use a left-handed grip, which means that the left shoulder is the most dominant.⁷

One of the greatest challenges to the clinician is understanding the role of proprioceptively mediated neuromuscular control after joint injury and its restoration through rehabilitation. Achieving functional and sport-specific activities after musculoskeletal trauma and rehabilitation can be enhanced significantly if proprioception is addressed and instituted in the treatment program.⁸ The contribution of proprioception to control of the upper limb is most evident at the most proximal joint, the shoulder. Poor osseous and capsuloligamentous glenohumeral joint stability necessitate a reliance on musculotendinous proprioception and stabilization more than any other joint in the human body.⁹ Several studies have confirmed the anatomic presence of a proprioceptive feedback mechanism in the shoulder.¹⁰⁻¹⁴ With increased stress and injury to the support structures of the glenohumeral joint, there may be a resultant compromise in

^aPrivate practice of chiropractic, Horrigan Sports Chiropractic Soft Tissue and Athletic Injuries, Los Angeles, Calif.

^bResident in diagnostic imaging, Los Angeles College of Chiropractic, Whittier, Calif.

This work was supported by the Los Angeles College of Chiropractic.

Submit reprint requests to: Chad E. Moreau, DC, Horrigan Sports Chiropractic Soft Tissue and Athletic Injuries, 2080 Century Park East, Ste 605, Los Angeles, CA 90067. E-mail: cemoreau@earthlink.net.

Paper submitted July 12, 2000.
doi:10.1067/mmt.2001.116423

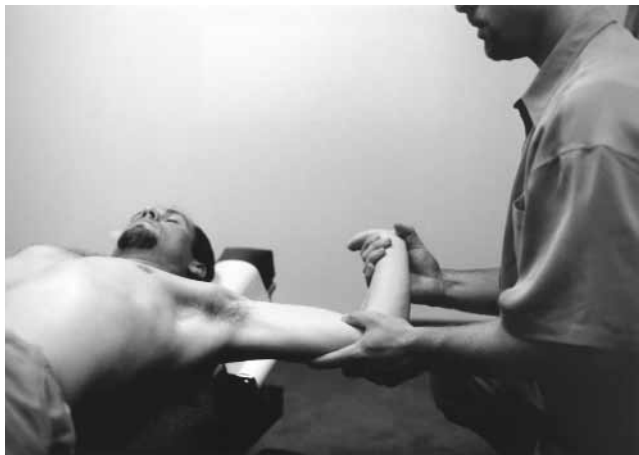

Fig 1. Test for proprioceptive response to sudden movements of the arm by the examiner.

a patient's ability to use proprioceptive information to control limb position. Injury to the capsule, labrum, ligaments, and surrounding muscles of the shoulder may result in damage to the neural mechanoreceptors that mediate normal proprioceptive sensation.¹⁵ This deficit could lead to slow protective reflexes, where muscle contraction occurs too late to protect the joint.¹ The deficit in proprioception that results may contribute to ongoing instability and injury of the shoulder joint.¹⁵

This case demonstrates the use of proprioceptive training and soft tissue mobilization and improving joint function in the management of a professional hockey player with recurrent shoulder instability. A novel outcome measure designed to evaluate quality of life issues related to shoulder instability was used to monitor the success of the intervention.² Although the measure used was subjective, the athlete's episodes of perceived instability were recorded to further demonstrate the effectiveness of the treatment protocol.

CASE REPORT

The patient was a 23-year-old professional National Hockey League player. The patient, who was 74 inches tall and weighed 205 pounds, had recurring left shoulder instability that began in 1996. He underwent Bankart shoulder repair surgery in 1996 and again in 1997 after the first repair appeared to be unsuccessful. The Bankart procedure uses the deltopectoral interval to access and incise the capsule and then to reattach the capsulolabral complex to the bony glenoid rim.¹⁶ The patient stated that a strengthening rehabilitation program was implemented after each surgery. He was fully recovered, and the surgeon subsequently released him to return to hockey. The most recent onset of shoulder instability began in October 1998 when the patient began to notice the shoulder "slipping out of the socket" and his left arm "going dead." The patient described the shoulder "going out" approximately 8 to 10 times in the first half of the current hockey season (October to January). The left shoulder would remain painful for 1 to 2 days after each episode. The

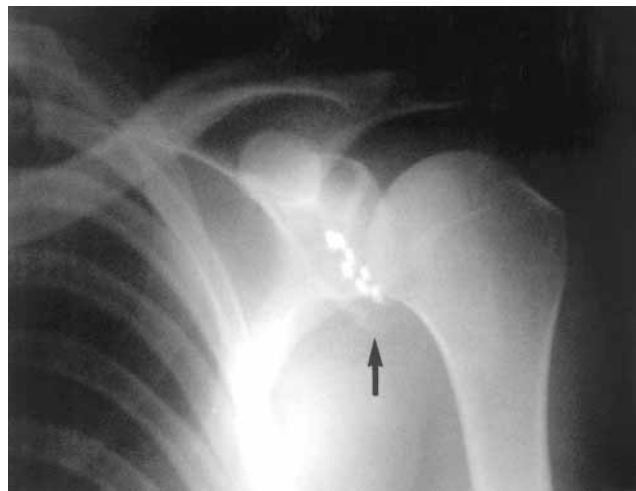


Fig 2. Anterior-posterior external rotation view of the left shoulder demonstrating Bankart-type lesion (arrow) and surgical artifacts.

patient noted the position of external rotation and abduction, or when the left hand and arm are moved suddenly into flexion above shoulder height, as the positions of perceived instability.

On physical examination, a 3-inch scar was noted over the left deltoid area from the two previous operations. Apprehension test was positive for the left shoulder. The load and shift test¹⁷ of the left shoulder revealed anterior instability with excessive passive translation of the humeral head on the glenoid. Motion palpation¹⁸ demonstrated tenderness and hypomobility of the left sternoclavicular, scapulothoracic, and acromioclavicular joints and the lower cervical spine. Tenderness was also detected in the infraspinatus and teres minor muscles. With inclinometric measurements, shoulder ranges of motion were normal and pain-free in all directions except left external rotation, which was limited by 20° and guarded. Neurologic testing was within normal limits for the upper and lower extremities. The patient demonstrated poor proprioceptive response of the left shoulder musculature to sudden movements of the left arm. This was tested with the patient supine, eyes closed, with the examiner applying internal and external rotatory forces to the forearm; the patient then had to quickly resist the movement (Fig 1). The left extremity response appeared delayed compared with the right extremity. The proprioception test described here was a crude modification of the method used to measure the threshold of detection of passive motion with a proprioceptive testing device.^{3,11,15,19,20}

Before visiting our office, the patient had radiographs and magnetic resonance imaging of the left shoulder. Anterior-posterior internal rotation, anterior-posterior external rotation, and axillary projection radiographs were performed. Alignment of the humeral head on the glenoid was normal. A 1.5-cm × 1.5-cm fragment of bone was seen at the anterior-inferior aspect of the glenoid rim, representing an osseous Bankart-type lesion (Fig 2). Seven metallic surgical artifacts were present at the inferior glenoid neck and rim, representing surgical anchors used in the previous surgeries. No signif-

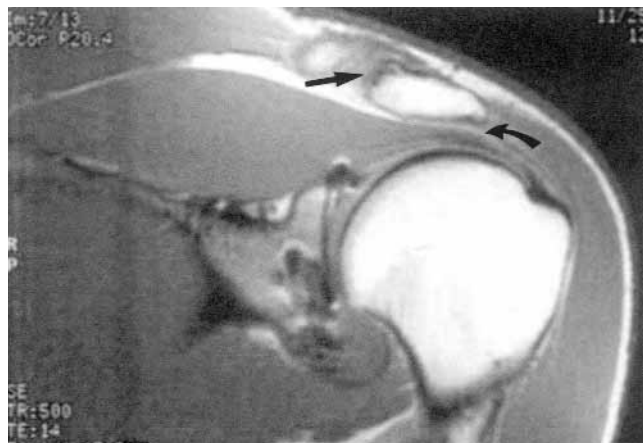


Fig 3. T1-weighted coronal magnetic resonance imaging demonstrating signal irregularities of the supraspinatus tendon (curved arrow). Also note low signal changes of the acromion, representing degeneration of the acromioclavicular joint (arrow).

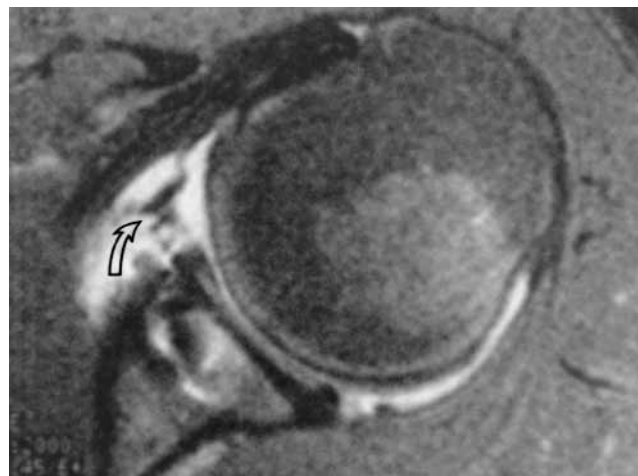


Fig 4. Proton density fast spin echo axial magnetic resonance imaging, demonstrating an apparent disruption of a portion of the glenohumeral ligament (curved arrow).

icant Hill-Sachs lesion was identified. T1, T2, and multiple fat-suppressed fast spin echo magnetic resonance imaging sequences in the coronal, axial, and sagittal oblique planes were obtained without contrast injection. They demonstrated a moderate amount of fluid, which was represented by high signal on T2, present within the capsule of the glenohumeral joint, especially in the axillary recess. This suggested probable joint effusion. There were low signal cystic changes at the acromial side of the acromioclavicular joint, representing degeneration of this joint (Fig 3). A region of inhomogeneous signal increase on T1, which was less evident on T2, was present within the supraspinatus tendon. The peribursal fat plane was intact. These abnormalities indicate supraspinatus tendinosis (Fig 3). Evaluation of the inferior and middle glenoid was difficult because of the presence of many metallic surgical artifacts; however, the integrity of the inferior glenoid labrum, subscapularis tendon, and posterior capsule were questionable. A portion of the glenohumeral ligament appeared to be disrupted and lax (Fig 4). The bicipital tendon and anterior glenoid labrum appeared intact. Magnetic resonance imaging evaluation of the shoulder after surgery was made difficult because of surgical distortion of soft tissue landmarks, incomplete information regarding surgical procedures, and unavailability of baseline studies before and after surgery.²¹ The imaging of this patient revealed anatomic lesions consistent with recurrent glenohumeral instability.

Two subjective outcome measures were used to measure the effectiveness of the treatment protocol in reducing the symptoms of recurrent shoulder instability. A disease-specific quality of life measurement tool for shoulder instability called the Western Ontario Shoulder Instability Index (WOSI)² was used to measure the patient's subjective impression of the success of the treatment protocol (Fig 5). In addition, because the patient first sought chiropractic care half way through the hockey season, a symptom diary was used to keep track of the number of episodes of shoulder instability in the second half of the hockey season.

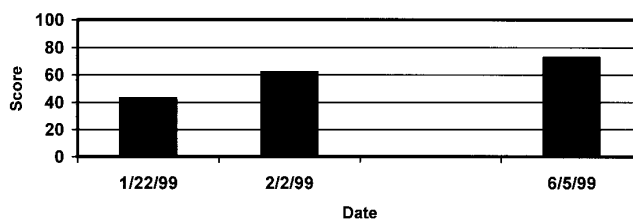


Fig 5. Scores for the Western Ontario Shoulder Instability Index. A score of 100 would indicate the patient had no decrease in shoulder-related quality of life.²

Initially the patient's hockey schedule only allowed him to seek chiropractic care for 3 consecutive days. The clinical plan for the first 3 visits was to use manual procedures to reduce the joint hypomobility in the sternoclavicular, acromioclavicular, and lower cervical joints and to perform soft tissue mobilization of the left shoulder musculature and surgical scar over the anterior deltoid area. The acromioclavicular joint was mobilized with the patient supine as the doctor, while positioned above the patient, placed the thenar eminence of one hand on the clavicle. With the other hand, the doctor fixed the axilla from below and sprung the joint in a craniocaudal direction with both hands.²² The sternoclavicular joint was mobilized in an inferior to superior direction with a bilateral thumb contact taken by the doctor on the patient's left sternoclavicular joint.¹⁸ High-velocity, low-amplitude manipulation was performed to the lower cervical spine. The large scar over the deltoid area of the left shoulder was treated²² by simple skin stretching of the hyperemic zone (area of increased redness) until the scar tissue became more similar in texture and appearance to the surrounding skin. Soft tissue mobilization was performed for the left rotator cuff musculature, focusing on the teres minor and infraspinatus. Proprioception was addressed by a series of exercises that the patient initially performed in the office

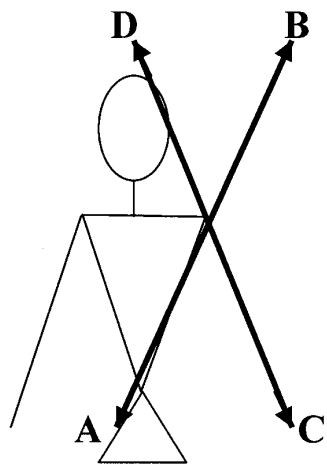


Fig 6. The PNF diagonals as described by Adler et al.²³ See text for explanation of positions A to D.



Fig 7. Proprioceptive exercise oscillating blade while balancing trunk on a gym ball. Strapping tape used for proprioceptive support.

Table 1. Summary of proprioceptive exercise program

Exercise	Frequency	Duration
PNF diagonals	Daily	To fatigue
PNF diagonals with resistance	3 to 4 times/wk	To fatigue
PNF diagonals with rhythmic impulse	3 to 4 times/wk	To fatigue
Push ups with plus on rockerboards	3 to 4 times/wk	20 repetitions initially
Oscillating blade while standing	3 to 4 times/wk	5 min each arm initially
Oscillating blade on gym ball	3 to 4 times/wk	5 min each arm initially
Catch 5-lb medicine ball on rockerboard	3 to 4 times/wk	20 times in various shoulder positions

PNF, Proprioceptive neuromuscular facilitation.

under supervision; the patient was then instructed to continue these exercises daily until he was able to return to the office. The exercises would take him from 20 to 30 minutes to complete. These exercises initially consisted of proprioceptive neuromuscular facilitation (PNF) diagonals for the upper extremity.²³ The PNF upper extremity patterns are useful to treat dysfunction caused by muscular weakness, poor coordination, and joint restriction.²³ The starting position for the first diagonal can be described as a “sword being placed in a sheath” on the right hip by the left hand (Fig 6, A). The patient’s left wrist and fingers are ulnar flexed, forearm pronated, shoulder adducted and internally rotated, and the scapula anteriorly depressed. The left arm then moved in a diagonal. The hand and wrist began the pattern by moving into radial extension. Subsequently the forearm is supinated, and the shoulder is flexed, abducted, and externally rotated. The scapula finished in posterior elevation. This can be described as the “waiter’s position” (Fig 6, B). A second diagonal started with wrist and hand ulnar extended, forearm pronated, shoulder extended, abducted, and internally rotated, and scapula posteriorly depressed in the “fending off” position (Fig 6, C). The extremity then moved in a diagonal to finish with the wrist and hand radially flexed, forearm supinated, shoulder flexed, adducted, and externally rotated, and scapula anteriorly elevated in a “shielding the head” position (Fig 6, D). The PNF diagonals were performed by the patient in a supine and standing position. The patient was also instructed to have the trainer of his hockey

team provide resistance and rhythmic impulses during the diagonal movements to increase the proprioceptive challenge.²³ The patient was instructed to perform exaggerated push up movements, or push ups “with a plus,” on two rockerboards to emphasize the serratus anterior and to again challenge the proprioceptive system. An oscillating 2.25 pound 5-foot plastic blade with a thickened handle in the middle was also used in multiple positions for both upper extremities (Fig 7). The long blade was oscillated and moved into flexion, abduction, and external rotation at the patient’s discretion. The first standing PNF diagonal was also done with the oscillating blade. Strapping tape was used during the exercise routine for interscapular integrity and proprioceptive support (Fig 7).²⁴ Nutritional supplements, consisting of proteolytic enzymes combined with bioflavonoids and vitamin C and increased ω -3 and ω -6 fatty acid consumption, were also recommended to decrease inflammation.²⁵

The patient returned for treatment 2 weeks later when his team played in the area. Again the patient filled out a WOSI questionnaire. The same manual procedures were performed, and the exercises were reviewed. The patient was encouraged to continue the exercise program for the remainder of the hockey season.

After the hockey season, the patient returned to the office for evaluation and one week of daily treatment. He stated that he had only felt the left shoulder “go out” twice since the onset of treatment. This seemed to be an improvement since the first half of the season for which he had reported 8

to 9 episodes of instability (Fig 8). The patient's reaction time to sudden impulsive movements of the left arm and shoulder seemed significantly improved compared with the right extremity. The patient recorded another WOSI score at this time. The emphasis of the rehabilitation program was to incorporate more open chain exercises (movement with the terminal joint free) into the program. We had the patient stand on a rockerboard and catch and throw a small medicine ball in various arm positions. Another exercise involved the patient lying on a gym ball prone while oscillating the proprioceptive blade overhead (Fig 7). This exercise seemed to involve much of the scapular and rotator cuff musculature. The manual procedures were continued as needed. The patient was released from care and instructed to continue the established exercise program on his own (Table 1).

DISCUSSION

This case demonstrated the successful use of chiropractic procedures and proprioceptive exercise to decrease the symptoms of recurrent shoulder instability. Trauma to tissues that contain mechanoreceptors may result in partial deafferentation, which can lead to proprioceptive deficits.²⁶ The consequence of a deficit in proprioception could result in a delay in efferent protective muscle activity.²⁶ Normal mechanoreceptor function as modulator of protective muscle responses is vital to prevention of joint injury and to minimize further damage to already injured or destabilized joints.⁹ This would suggest that the type of conservative approach used in this case for a patient with shoulder instability should be considered regardless of whether the patient is a surgical candidate.

The key strategy of this treatment approach was based on the role of proprioceptively mediated neuromuscular control after joint injury and its restoration through rehabilitation. Because several interventions were used simultaneously, it is impossible to determine which intervention had the greatest impact on decreasing the shoulder symptoms. The patient still described incidences of shoulder instability during the treatment period, but at a lesser rate than before treatment was initiated (Figs 5 and 8).

The patient demonstrated a 30-point increase on the WOSI scores from the initial visit to the final follow-up visit 5½ months later. Because the patient's perception of changes of health status was probably the most important indicator of the success of the treatment protocol, a 30-point increase on a 100 point scale for the WOSI was a significant improvement.² The patient symptom diary also demonstrated a significant decrease in episodes of disability during the hockey season after the start of treatment.

Ultimately, the treatment success could have been more objectively measured with a proprioceptive testing device. In this device, the subject's shoulder is positioned in 90 degrees of elbow flexion and shoulder abduction and the testing device is moved into external rotation. The time it takes the subject to sense the shoulder motion is the threshold to detection of motion, which is a measure of proprioceptive sensibility. In the studies that used the proprioceptive testing device, there were significant differences

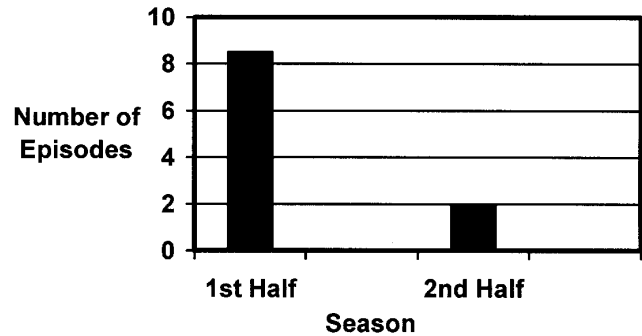


Fig 8. Number of episodes of instability reported by the patient during the hockey season. The first half of the season was from October to January. The second half of the season was from January to May.

between subjects with stable versus unstable shoulders.^{3,11,15,19,20} Unfortunately such a device is expensive and not practical in the office setting. In this case, although the patient demonstrated subjective improvement of shoulder symptoms, which allowed him to play the entire season, he is still contemplating a third surgery because of the perceived effects of the shoulder instability on his ability to adequately prepare and compete in his sport.

Of course this treatment protocol cannot be generalized to be deemed effective for all cases of shoulder instability. Each specific treatment protocol should be designed with the athlete's sporting demands in mind. In this case the athlete felt the most unstable with impulsive movements into flexion, external rotation, and abduction. Therefore the emphasis of the exercise program was to attempt to increase proprioceptively mediated neuromuscular control in these positions. Although the treatment intervention did not objectively demonstrate an increase in proprioceptively mediated neuromuscular control, it did demonstrate a subjective decrease in the athlete's symptoms of recurrent shoulder instability. In addition, although the contribution of the ligaments and muscles towards shoulder stability is essential and ongoing at any given time, the shoulder is not intended to sustain extreme loads applied with high accelerations. In fact, application of such high and fast loads as occur in sports trauma is the major cause of structural shoulder damage. These events are beyond the capabilities of any stabilizing influence.²⁷

CONCLUSION

This case demonstrates how an athlete with recurrent shoulder instability had a successful outcome after receiving multimodal treatment of soft tissue mobilization, manipulation, proprioceptive training and taping, nutritional counseling, and conditioning exercises. It further demonstrates that achieving functional and sport-specific activities after musculoskeletal trauma can be enhanced significantly if proprioception is addressed in the treatment program. The decreased frequency of instability occurrences in this case combined with the perceived improvement on the shoulder instability index suggest a gradual stabilization of the proprio-

ceptive function of the shoulder. This would suggest that rehabilitation exercises should focus on the importance of incorporating joint position sensibility and reflexive-type contractions into the therapy program. Future directions for proprioception research should consider the effects of upper extremity training on proprioception in both normal and unstable shoulders. Future studies should also examine the effectiveness of proprioceptive training in nonoperative treatment of shoulder instability. Further research to better understand and use chiropractic management strategies and interventions for athletes with shoulder instability appears warranted.

ACKNOWLEDGMENTS

We thank Bart Green, DC, Joseph Horrigan, DC, and Jeffrey Cooley, DC, for their assistance with this project.

REFERENCES

1. Forwell LA, Carnahan H. Proprioception during manual aiming in individuals with shoulder instability and controls. *J Orthop Sports Phys Ther* 1996;23:111-9.
2. Kirkley A, Griffin S, McLintock H, Ng L. The development and evaluation of a disease-specific quality of life measurement tool for shoulder instability (The Western Ontario Shoulder Instability Index). *Am J Sports Med* 1998;26:764-72.
3. Smith RL, Brunolli J. Shoulder kinesthesia after glenohumeral joint dislocation. *Phys Ther* 1989;69:106-12.
4. Dines DM, Levinson M. The conservative management of the unstable shoulder including rehabilitation. *Clin Sports Med* 1995;14:797-816.
5. Flatow EL, Miniaci A, Evans PJ, Simonian PT, Warren RF. Instability of the shoulder: complex problems and failed repairs: part II. Failed repairs. *Instr Course Lect* 1998;47:113-25.
6. Pforringer W, Smasal V. Aspects of traumatology in ice hockey. *J Sports Sci* 1987;5:327-36.
7. Hovelius L. Shoulder dislocations in Swedish ice hockey players. *Am J Sports Med* 1978;6:373-7.
8. Lephart SM, Pincivero DM, Giraldo JL, Fu FH. The role of proprioception in the management and rehabilitation of athletic injuries. *Am J Sports Med* 1997;25:130-7.
9. Nyland JA, Caborn DN, Johnson DL. The human glenohumeral joint. A proprioceptive and stability alliance. *Knee Surg Sports Traumatol Arthrosc* 1998;6:50-61.
10. Vangsness Jr CT, Ennis M, Taylor JG, Atkinson R. Neural anatomy of the glenohumeral ligaments, labrum, and subacromial bursa. *Arthroscopy* 1995;11:180-4.
11. Jerosch J, Steinbeck J, Clahsen H, Schmitz-Nahrath M, Grosse-Hackmann A. Function of the glenohumeral ligaments in active stabilization of the shoulder joint. *Knee Surg Sports Traumatol Arthrosc* 1993;1:152-8.
12. Tibone JE, Fechter J, Kao JT. Evaluation of a proprioception pathway in patients with stable and unstable shoulders with somatosensory cortical evoked potentials. *J Shoulder Elbow Surg* 1997;6:440-3.
13. Voight ML, Hardin JA, Blackburn TA, Tippet S, Canner GC. The effects of muscle fatigue on and the relationship of arm dominance to shoulder proprioception. *J Orthop Sports Phys Ther* 1996;23:348-52.
14. Gohlke F, Janssen E, Leidel J, Heppelmann B, Eulert J. Histopathologic findings in the proprioception of the shoulder joint. *Orthopade* 1998;27:510-7.
15. Lephart SM, Warner JJP, Borsa PA, Fu FH. Proprioception of the shoulder joint in healthy, unstable, and surgically repaired shoulders. *J Shoulder Elbow Surg* 1994;3:371-80.
16. Longobardi RS, Rafii M, Minkoff J. MR imaging of the post-operative shoulder. *MRI Clin North Am* 1997;5:841-59.
17. Wilk KE, Andrews JR, Arrigo CA. The physical examination of the glenohumeral joint: Emphasis on the stabilizing structures. *J Orthop Sports Phys Ther* 1997;25:380-9.
18. Bergmann TF, Peterson DH, Lawrence DJ. Extraspinal techniques. In: *Chiropractic techniques*. New York: Churchill Livingstone; 1993. p. 580-1.
19. Blasier RB, Carpenter JF, Huston LJ. Shoulder proprioception. Effect of joint laxity, joint position, and direction of motion. *Orthop Rev* 1994;23:45-50.
20. Machner A, Wissel H, Heitmann D, Pap G. Changes in proprioceptive capacities of the shoulder joint in ventral shoulder instability. A comparative study before and after arthroscopic labrum refixation. *Sportverletz Sportschaden* 1998;12:138-41.
21. Resnick D. Internal derangements of joints. In: *Diagnosis of bone and joint disorders*. 3rd ed. Philadelphia: WB Saunders; 1995. p. 3013.
22. Lewit K. Therapeutic techniques. In: *Manipulative therapy in rehabilitation of the locomotor system*. 2nd ed. Oxford: Reed Educational and Professional Publishing; 1991. p. 151-2.
23. Adler SS, Beckers D, Buck M. The upper extremity. In: *PNF in practice, an illustrated guide*. Berlin, Germany: Springer-Verlag; 1993. p. 67-102.
24. Brown T. Current concepts in functional taping. *Proceedings of the Chiropractic Sports Sciences Symposium*; 1997 April 3-6; Los Angeles.
25. Werbach MR. Sports injuries. In: *Nutritional influences on illness*. 2nd ed. California: Third Line Press; 1996. p. 589-90.
26. Wallace DA, Beard DJ, Gill RHS, Eng B, Carr AJ. Reflex muscle contraction in anterior shoulder instability. *J Shoulder Elbow Surg* 1997;6:150-5.
27. Guanche C, Knatt T, Solmonow M, Lu Y, Baratta R. The synergistic action of the capsule and the shoulder muscles. *Am J Sports Med* 1995;23:301-6.